

DEXMEDETOMIDINE AND CLONIDINE AS ADJUVANTS TO LEVOBUPIVACAINE IN SUPRACLAVICULAR BRACHIAL PLEXUS BLOCK: A COMPARATIVE RANDOMISED PROSPECTIVE CONTROLLED STUDYKarthik G. S¹, Sudheer R², Sahajananda H³, S. Rangalakshmi⁴, Roshan Kumar⁵**HOW TO CITE THIS ARTICLE:**

Karthik G. S, Sudheer R, Sahajananda H, S. Rangalakshmi, Roshan Kumar. "Dexmedetomidine and Clonidine as Adjuvants to Levobupivacaine in Supraclavicular Brachial Plexus Block: A Comparative Randomised Prospective Controlled Study". Journal of Evolution of Medical and Dental Sciences 2015; Vol. 4, Issue 19, March 05; Page: 3207-3221, DOI:10.14260/jemds/2015/466

ABSTRACT: BACKGROUND: There are always efforts to find better and safer local anaesthetics along with adjuvants for supraclavicular brachial plexus block. Levobupivacaine, has strongly emerged as a safer alternative for regional anesthesia than its racemic sibling, bupivacaine. Alpha 2 agonists are combined with local anaesthetics to improve the quality of regional anesthesia. **AIMS AND OBJECTIVES:** This study was conducted to evaluate and compare the onset, duration of sensory and motor blockade along with the duration of analgesia between dexmedetomidine and clonidine when administered along with 0.5% levobupivacaine in supraclavicular brachial plexus block for upper limb orthopaedic surgeries. **MATERIALS AND METHODS:** A prospective randomized study was carried out in the department of Anaesthesia at Rajarajeswari Medical College and Hospital which included 50 adult patients between the ages of 20 and 50 years (of ASA I/II grade) who underwent upper limb orthopaedic surgeries. The patients were randomly allocated into two groups; levobupivacaine + dexmedetomidine (LD) and levobupivacaine + clonidine (LC), comprising of 25 patients each. Group LD was administered 30 ml of 0.5% levobupivacaine and 1µg/kg of dexmedetomidine, while group LC received admixture of 30 ml of 0.5% levobupivacaine and 1 µg/kg of Clonidine. Onset, duration of sensory and motor blockade and duration of analgesia were observed. **STATISTICAL ANALYSIS:** Statistical analysis was done using student t test, chi-square test and Fisher Exact test. The Statistical Software namely SAS 9.2, SPSS 15.0, Stata 10.1, MedCalc 9.0.1, Sysstat 12.0 and R environment ver.2.11.1 were also used for the analysis of the data and Microsoft word and Excel have been used to generate graphs, tables etc. The value of P <0.05 was considered significant and P < 0.001 as highly significant. **RESULTS:** The onset of sensory and motor blockade was faster in Group LD when compared to Group LC. The duration of sensory blockade, motor blockade and analgesia was longer in Group LD when compared to Group LC (p <0.001). Sedation scores were better in LD group. (p<0.05). **CONCLUSION:** Dexmedetomidine is a better adjuvant than Clonidine when added to Levobupivacaine in supraclavicular brachial plexus block as it prolongs the duration of sensory and motor blockade as well as the duration of analgesia. **KEYWORDS:** Clonidine, dexmedetomidine, supraclavicular brachial plexus block, levobupivacaine, upper limb orthopaedic surgeries.

INTRODUCTION: Levobupivacaine is a local anaesthetic with long duration of action, having similar pharmacology to bupivacaine; however, it has a wider safety margin and was shown to possess less cardiotoxicity in comparison with bupivacaine.^(1,2,3)

Alpha 2 adrenergic agonists have both analgesic and sedative properties when used as an adjuvant in regional anaesthesia.^(4,5,6) They have been reported to improve the quality of regional

ORIGINAL ARTICLE

anaesthesia. The anaesthetic and the analgesic requirement gets reduced to a huge extent by the use of these two adjuvants (i.e. dexmedetomidine and clonidine) because of their analgesic properties and augmentation of local anaesthetic effects.^(7,8,9)

Keeping their pharmacologic interactions and other beneficial properties we planned a double blind prospective randomized clinically controlled study at our institute with an aim to compare the onset and duration of sensory and motor blockade along with the ability to provide smooth intraoperative and post-operative analgesia by both these drugs when used in supraclavicular brachial plexus block as an adjuvant to levobupivacaine in patients undergoing upper limb orthopaedic surgeries.

METHODS: A prospective randomized double blind controlled study was done after taking the approval from the ethical committee of Rajarajeshwari Medical College and Hospital. 50 patients of ASA I & II physical status aged between 20-50 yrs scheduled to undergo elective upper limb orthopaedic surgeries under supraclavicular brachial plexus block were enrolled for the study and were randomly allocated into two groups based on a computer generated code.

Group LD (n=25) = patients received 30 ml of 0.5% levobupivacaine with dexmedetomidine 1µg/kg.

Group LC (n=25) = patients received 30 ml of 0.5% levobupivacaine with clonidine 1µg/kg.

The patients with haematological disease, ASA III or greater, bleeding or coagulation test abnormalities, severe renal or hepatic derangement, local site infection, psychiatric diseases, peripheral vascular disease, diabetes, history of drug abuse and allergy to local anaesthetics of the amide type, pregnant and lactating women were excluded from the study.

Patients taking adrenoceptor agonist or antagonist therapy, chronic analgesic therapy, any anticoagulants and diagnosed to have poorly controlled hypertension, hypotension, angina and cardiopulmonary disease were also not considered.

The study solutions were prepared by an anaesthesiologist not involved in the proceedings. A prospective randomized double blind study was planned. Patient and anaesthesiologist who performed the supraclavicular brachial plexus block were blinded by the study solutions. The statistician who analysed the results was unaware of group allocation and aim of the study.

In the operation theatre, a good peripheral intravenous access was secured using 18 gauge canula in the unaffected limb and Ringer's Lactate infusion was started.

Baseline noninvasive blood pressure, pulse rate, electrocardiograph and pulse oximetry were recorded.

Patients were administered brachial plexus block by supraclavicular route via the subclavian perivascular approach in supine position with arm adducted and head turned about 30 degrees to the contralateral side. Under all aseptic precautions, the injection site was identified about 1 cm behind the midpoint of the clavicle, (where the pulsation of the subclavian artery was felt) and 1 ml of 2% lignocaine was infiltrated subcutaneously. A nerve stimulator was used to locate the brachial plexus. The needle was directed just above and posterior to the subclavian pulse caudally at a very flat angle against the skin. The location end point was a distal motor response, that is, the movement of the fingers with an output current lower than 0.5 mA. During injection of the drug solution negative aspiration was done to avoid intravascular injection. Plexus block was considered successful when at least two out of the four nerve territories (ulnar, radial, median and musculocutaneous) were effectively blocked for both sensory and motor block.

ORIGINAL ARTICLE

Sensory block was assessed by pin prick test using a 3 point scale: 0=normal sensation, 1=loss of sensation of pin prick (analgesia), 2=loss of sensation of touch. Motor blockade was determined according to modified Bromage scale on a 3-point scale.

Grade 0=Normal motor function with full flexion and extension of elbow, wrist, and fingers
Grade 1=Decreased motor strength with ability to move the fingers only
Grade 2=Complete motor block with inability to move the fingers.

Thumb abduction (radial nerve) thumb opposition (median nerve), thumb adduction (ulnar nerve) and flexion of the elbow (musculocutaneous nerve) was assessed. Both sensory and motor blocks was assessed every 3 min till their onset and at 15, 30, 45, 60, 90, and 120 min; and then hourly (even after surgery) after the completion of injection, until they had resolved. Patients were asked to note the subjective recovery of sensation and movements which was then certified by an anesthesiologist. Onset time for sensory block was defined as the time interval between the end of local anesthetic administration and complete sensory block (score 2 for all nerves). Duration of sensory block was defined as the time interval between the complete sensory block and complete resolution of anesthesia on all the nerves (score 0). Onset time for motor block was defined as the time interval between total local anesthetic administration and complete motor block (grade 2). Duration of motor block was defined as the time interval from complete motor block to complete recovery of motor function of hand and forearm (grade 0).

HR, SBP, and DBP were recorded at 0, 5, 10, 15, 30, 45, 60, 90, 120 and 180 minutes. Sedation score was assessed according to the modified Ramsay Sedation Scale (RSS) from 1-6 as follows: 1 = anxious, agitated, restless; 2 = cooperative, oriented, tranquil; 3 = responds to commands only; 4 = brisk response to light glabellar tap or loud noise; 5 = sluggish response to light glabellar tap or loud noise; 6 = no response. Adverse effects like hypotension (i.e., 20% decrease relative to baseline), bradycardia (HR <50 beats/min), nausea, vomiting, and hypoxemia (SpO₂ <90%) if occurred were noted. Any need for additional medications were noted intraoperatively. The time between the complete sensory block and the first analgesic request was recorded as duration of analgesia (DOA). Pain was assessed using visual analogue scale (VAS) 0-10. The data was compiled and subjected to statistical analysis using SAS 9.2, SPSS 15.0, Stata 10.1, MedCalc 9.0.1, Sysstat 12.0 and R environment ver.2.11.1 and Microsoft word and Excel have been used to generate graphs, tables etc. Demographic and hemodynamic data was subjected to Student t-test and Fisher exact test. For statistical analysis of onset, time, duration of sensory and motor blockade and duration of analgesia, unpaired t-test was applied. P-value < 0.05 was considered as statistically significant and P < 0.001 as highly significant.

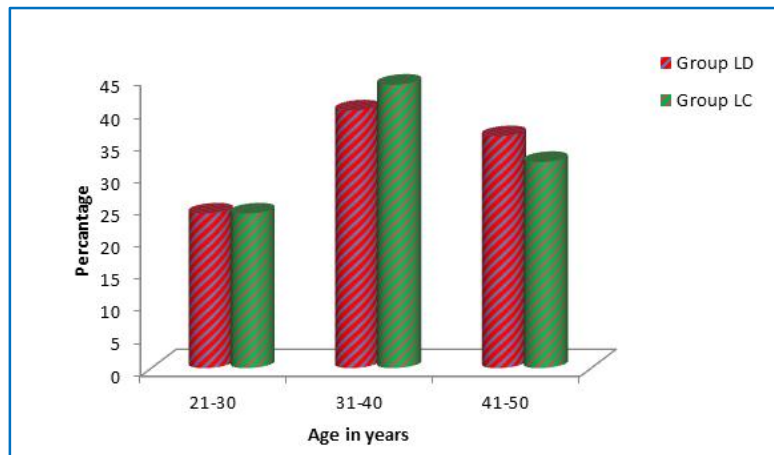
STUDY DESIGN: A comparative two group study

Age in years	Group LD	Group LC	Total
21-30	6(24%)	6(24%)	12(24%)
31-40	10(40%)	11(44%)	21(42%)
41-50	9(36%)	8(32%)	17(34%)
Total	25(100%)	25(100%)	50(100%)
Mean ± SD	36.84±8.19	36.16±7.19	36.50±7.64

Table 1: Age distribution of patients studied

Samples are age matched with P=0.757.

ORIGINAL ARTICLE



GRAPH 1

LD=levobupivacaine + dexmedetomidine, LC = levobupivacaine + clonidine.

Gender	Group LD	Group LC	Total
Female	12(48%)	12(48%)	24(48%)
Male	13(52%)	13(52%)	26(52%)
Total	25(100%)	25(100%)	50(100%)

Table 2: Gender distribution of patients studied

Samples are gender matched with $P=1.000$.

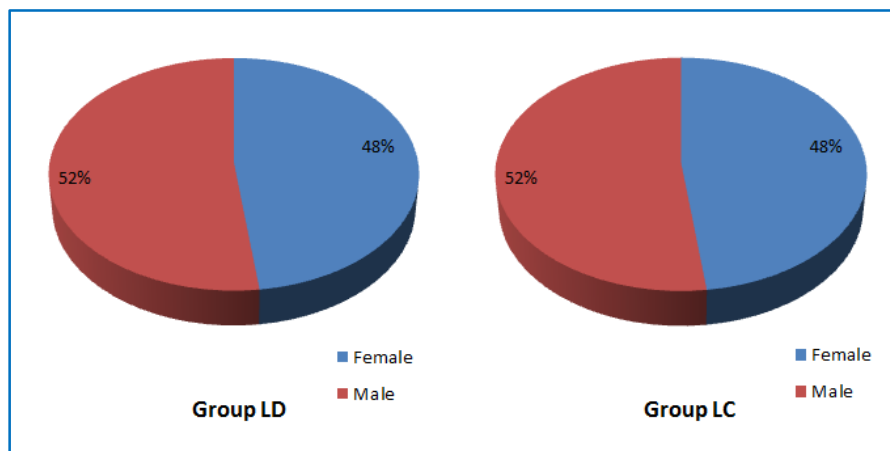


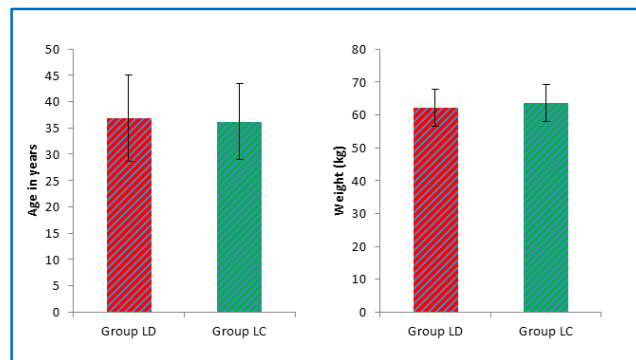
FIGURE 1

LD = levobupivacaine + dexmedetomidine, LC = levobupivacaine + clonidine.

ORIGINAL ARTICLE

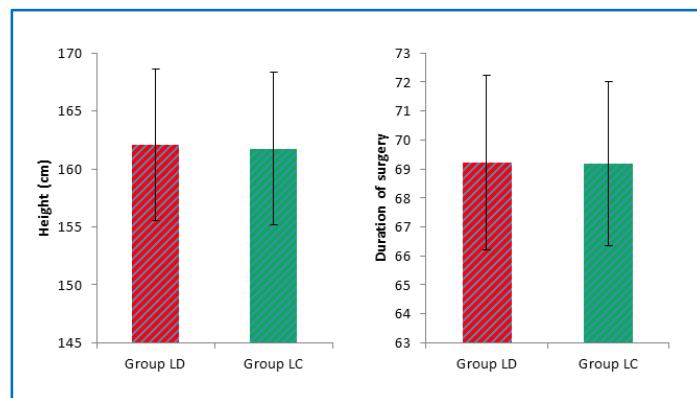
	Group LD	Group LC	Total	P value
Age in years	36.84±8.20	36.16±7.19	36.50±7.64	0.757
Weight (kg)	62.20±5.63	63.60±5.65	62.90±5.63	0.384
Height (cm)	162.10±6.55	161.76±6.62	161.93±6.52	0.856
Mean Duration of surgery	69.22±3.01	69.18±2.82	69.20±2.89	0.962

Table 3: Comparison of baseline variables in two groups studied



GRAPH 2

LD = levobupivacaine + dexmedetomidine, LD = evobupivacaine + dexmedetomidine,
 LC = levobupivacaine + clonidine LC = levobupivacaine + clonidine.



GRAPH 3

LD=levobupivacaine+dexmedetomidine,
 LC=levobupivacaine+clonidine

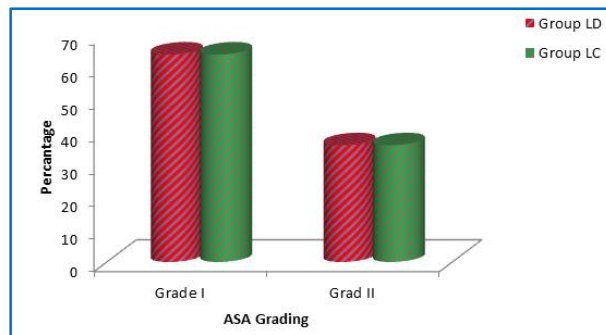
LD=levobupivacaine+dexmedetomidine,
 LC=levobupivacaine+clonidine.

ORIGINAL ARTICLE

ASA Grading	Group LD	Group LC	Total
Grade I	16(64%)	16(64%)	32(64%)
Grad II	9(36%)	9(36%)	18(36%)
Total	25(100%)	25(100%)	50(100%)

Table 4: ASA Grading in two groups studied

ASA distribution is statistically similar with P=1.000.



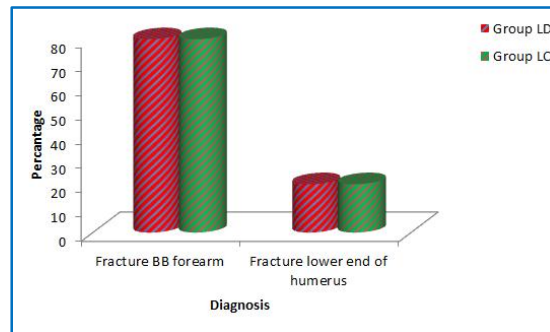
GRAPH 4

LD=levobupivacaine + dexmedetomidine, LC = levobupivacaine + clonidine.

Diagnosis	Group LD	Group LC	Total
Fracture BB forearm	20(80%)	20(80%)	40(80%)
Fracture lower end of humerus	5(20%)	5(20%)	10(20%)
Total	25(100%)	25(100%)	50(100%)

Table 5: Diagnosis in two groups of patients studied

Not significant with P=1.000.



GRAPH 5

LD = levobupivacaine + dexmedetomidine, LC=levobupivacaine + clonidine.

ORIGINAL ARTICLE

Surgery Underwent	Group LD	Group LC	Total
ORIF with plating for fracture BB forearm	20(80%)	20(80%)	40(80%)
ORIF with plating for lower end of humerus	5(20%)	5(20%)	10(20%)
Total	25(100%)	25(100%)	50(100%)

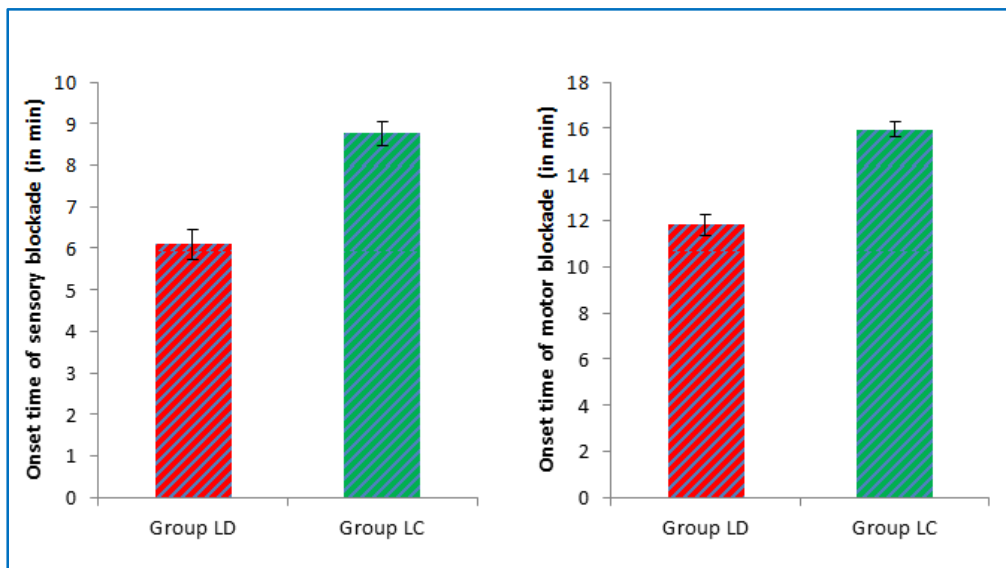
Table 6: Surgery Underwent in two groups of patients studied

P=1.000, Not significant, Fisher Exact test, LD=levobupivacaine + dexmedetomidine, LC=levobupivacaine + clonidine.

	Group LD	Group LC	P value
Onset time of sensory blockade (in min)	6.09±0.37	8.77±0.29	<0.001**
Onset time of motor blockade (in min)	11.81±0.44	15.94±0.32	<0.001**
Duration of sensory blockade (in min)	517.08±15.09	396.43±13.68	<0.001**
Duration of motor blockade (in min)	415.60±19.22	299.30±19.21	<0.001**
Duration of analgesia (in min)	616.74±20.98	507.81±24.58	<0.001**

Table 7: Comparison of Study variables in two groups studied

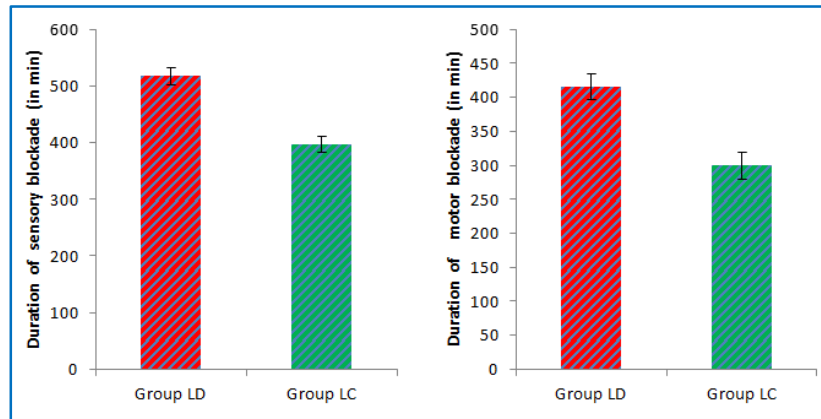
LD=levobupivacaine + dexmedetomidine, LC=levobupivacaine + clonidine.



GRAPH 6

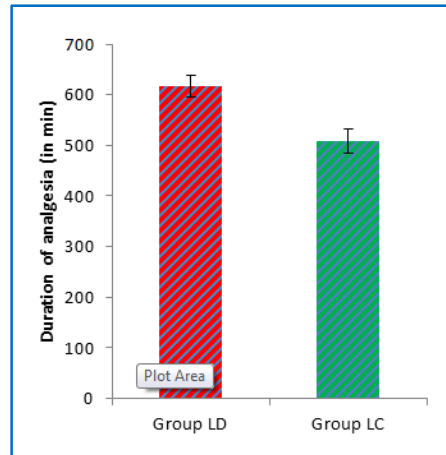
LD=levobupivacaine + dexmedetomidine, LC = levobupivacaine + clonidine.

ORIGINAL ARTICLE



GRAPH 7

LD=levobupivacaine + dexmedetomidine, LC = levobupivacaine + clonidine.



GRAPH 8

LD=levobupivacaine + dexmedetomidine, LC = levobupivacaine + clonidine.

Sedation score	Group LD(n=25)	Group LC
1	0	0
2	7 (28%)	11(44%)
3	8(32%)	10(40%)
4	10 (40%)	4(16%)
5	-	-
6	-	-

Table: 8 Comparison of Sedation scores in both the groups

P<0.05 =significant, fisher exact test.

LD = levobupivacaine + dexmedetomidine, LC = levobupivacaine + clonidine.

ORIGINAL ARTICLE

Duration	Group LD	Group LC
Baseline	84	86
5 min	82	80
10 min	80	78
15 min	78	76
30 min	77	75
45 min	68	70
60 min	66	68
90 min	62	64
120 min	64	65
180 min	66	68

Table 9: Comparison of pulse rate in both the groups

Pulse rate in both the groups were comparable without any statistical significance. ($p > 0.05$)
LD=levobupivacaine + dexmedetomidine, LC=levobupivacaine + clonidine.

GRAPHICAL REPRESENTATION OF COMPARISON OF PULSE RATE IN BOTH THE GROUPS:

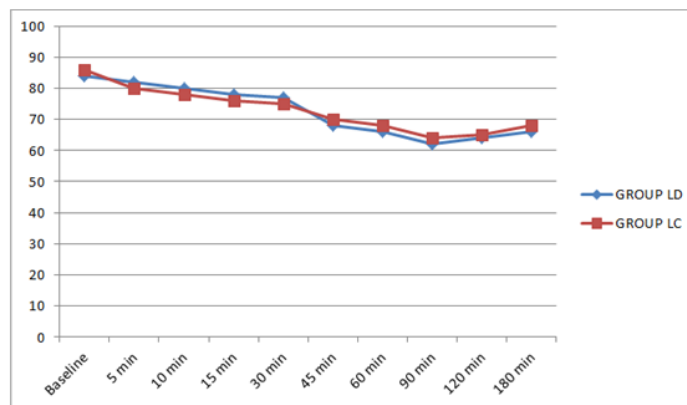


FIGURE 2

LD=levobupivacaine + dexmedetomidine, LC = levobupivacaine + clonidine.

Duration	Group LD	Group LC
Baseline	88	86
5 min	86	84
10 min	86	84
15 min	85	85
30 min	82	84
45 min	80	84
60 min	77	80
90 min	74	78
120 min	74	76
180 min	72	75

Table 10: Comparison of mean arterial pressure (MAP) in both the groups

ORIGINAL ARTICLE

The mean arterial pressures were comparable in both the groups without any statistical significance ($P>0.05$).

LD = levobupivacaine + dexmedetomidine, LC = levobupivacaine + clonidine.

GRAPHICAL REPRESENTATION OF COMPARISON OF MEAN ARTERIAL PRESSURE (MAP) IN BOTH THE GROUPS.

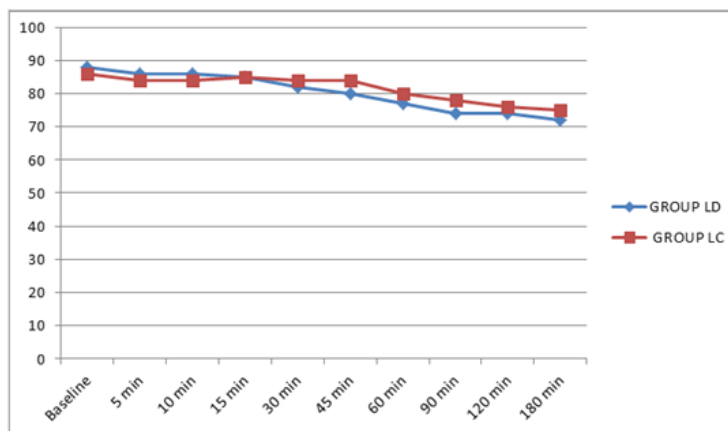


FIGURE 3

LD = levobupivacaine + dexmedetomidine, LC = levobupivacaine + clonidine.

RESULTS: 50 patients were enrolled for the study as mentioned and were randomly divided into two groups. The demographic profiles of patients in both the groups were comparable with regards to age, sex distribution, weight and height (Table 1, 2 and 3). The onset time for sensory and motor blockade were significantly shorter in LD group than LC group (Table 7) with $P < 0.001$ i.e., addition of dexmedetomidine resulted in earlier onset (6.09 ± 0.37) of sensory blockade and motor blockade (11.81 ± 0.44) when compared to addition of clonidine (8.77 ± 0.29) and (15.94 ± 0.32) (table 7). Sedation scores were significantly higher in LD group when compared to LC group ($P < 0.05$) (table 8). The duration of sensory blockade was longer in LD group (517.08 ± 15.09) as compared to LC group (396.43 ± 13.68) with $P < 0.001$. The duration of motor blockade was also better in LD group (415.60 ± 19.22) when compared to LC group (299.30 ± 19.21) ($P < 0.001$). Dexmedetomidine provided a smooth and prolonged post-operative analgesia (616.74 ± 20.98) as compared to clonidine (507.81 ± 24.58) (Table 7) ($P < 0.001$).

No side effects like nausea, vomiting, headache, dizziness, hypotension, respiratory depression were reported in either group. When compared to the basal heart rate, heart rate levels in both the groups were low but did not fall below 60 beats/min. Addition of dexmedetomidine to levobupivacaine in this study provided superior block characteristics along with smooth and prolonged post-operative analgesia as compared to clonidine (Table 7).

DISCUSSION: Brachial plexus block is commonly performed for surgeries on upper limb. The trunks of the brachial plexus carry the entire sensory, motor and sympathetic innervations of the upper extremity with predictable dense anaesthesia with high success rate.⁽¹⁰⁾

ORIGINAL ARTICLE

Different studies have compared levobupivacaine, ropivacaine and bupivacaine in brachial plexus block for upper limb surgery.^(11,12) Levobupivacaine is a good substitute for bupivacaine. Compared to ropivacaine, levobupivacaine provides a significantly longer duration of analgesia. The long duration of sensory block associated with good analgesia and less toxicity of levobupivacaine makes it a better choice for upper extremity blocks. Levobupivacaine 0.5% provided a longer duration of sensory block after sciatic nerve block than the same dose of ropivacaine in foot and ankle surgery. The use of a single dose of 0.5% levobupivacaine to block the tibial and peroneal nerves for hallux valgus surgery using popliteal approach is preferable over 0.5% ropivacaine for good anesthesia and better control of post-operative pain. Levobupivacaine 0.5% is as effective as bupivacaine 0.5% and is recommended for the 3-in-1 block. The quality and duration of peripheral nerve block is improved with the use of higher concentrations of levobupivacaine, (0.5-0.75%). Levobupivacaine administered via a peripheral nerve block continuous catheter provides excellent post-operative analgesia and decreases the post-operative systemic opioids requirements.^(13,14,15,16)

It has been postulated that presynaptic activation of alpha-2A adrenoceptor in the locus ceruleus inhibits the release of nor-epinephrine and results in the sedative and hypnotic effects and terminates the propagation of pain signals leading to analgesia. High selectivity for alpha 2A receptors mediates analgesia, sedation and anxiolysis.^(17,18,19)

Alpha 2 adrenergic agonists become popular because of their sedative, analgesic, antihypertensive, antiemetic actions in addition to reducing the anaesthetic drugs requirement. Alpha 2 adrenergic agonists have been tried either alone or in combination with other drugs, in epidural, intrathecal and peripheral injections, to prolong the duration of anaesthesia.^(20,21,22)

Animal studies conducted by Brumett et al⁽²³⁾ and Kousugi et al⁽²⁴⁾ showed that dexmedetomidine enhanced the duration of anaesthesia and analgesia. They found higher concentrations of dexmedetomidine inhibiting compound action potentials in a concentration dependant manner.

Although few human trials have been conducted, several studies have concluded that alpha -2 agonists are safer and effective adjuvants to local anaesthetics for various regional and neuraxial anaesthetic techniques. Taking this fact into consideration we decided to compare the efficacy of dexmedetomidine and clonidine as adjuvants to levobupivacaine in supraclavicular brachial plexus block. Although dexmedetomidine has a α_2/α_1 selectivity ratio that is eight-times higher than that of clonidine, an equipotent comparative study of both the drugs in peripheral nerve block was not available at the time of our study. Abosedira MA et al⁽²⁵⁾ showed that the quality of anaesthesia was significantly better in the Dexmedetomidine group compared to the Clonidine group. Patients in the Dexmedetomidine group were more sedated briefly post-operatively. This study reveals that, adding dexmedetomidine to lidocaine during Bier's block is better than adding clonidine.

AgarwalSandhya et al⁽²⁶⁾ in their study showed that dexmedetomidine is a useful adjuvant to bupivacaine in brachial plexus block. Swami et al⁽²⁷⁾ compared clonidine and dexmedetomidine as an adjuvant to local anaesthetic agent in supraclavicular brachial plexus block with respect to onset and duration of sensory and motor block and duration of analgesia. They showed significant increase in duration of analgesia on addition of dexmedetomidine to bupivacaine 0.25% in brachial plexus block. Our findings were similar to Saumya Biswas et al⁽²⁸⁾ who also demonstrated that addition of dexmedetomidine to levobupivacaine prolonged the duration of sensory and motor blockade along with increased duration of post-operative analgesia.

ORIGINAL ARTICLE

Memics D et al⁽²⁹⁾ and Esmaoglu et al⁽³⁰⁾ have shown that a dexmedetomidine-lignocaine mixture improved the quality of anesthesia and tourniquet pain and reduced postoperative analgesic requirement in Bier's block.

Some studies have shown that addition of clonidine to local anaesthetics in brachial plexus block have extended the duration of anaesthesia and increased the quality of analgesia, but Erlacher et al⁽³¹⁾ did not find much advantage in addition of clonidine to ropivacaine. Masuki et al⁽³²⁾ suggested that dexmedetomidine induces vasoconstriction via alpha 2 receptors in the human forearm (around the site of injection) which might delay the absorption of local anaesthetics thus prolonging their effects.

In our study none of the patients in both the groups required sedation which can be explained on the basis of some amount of systemic absorption of the drug. Alpha 2 agonists produce sedation by central action of inhibition of substance P release in the nociceptive pathway. But dexmedetomidine provided better arousable sedative effects when compared to clonidine.

In this study we have demonstrated that Dexmedetomidine shortened the onset time of both sensory and motor blockade. It also prolonged the duration of sensory and motor blockade as well as duration of analgesia when compared to Clonidine.

The heart rate was lower in both the groups when compared to the basal value. Further studies are needed to determine the side effects and the safe optimal dose of alpha 2 agonists.

Although Clonidine still continues to be used widely due to its lower cost, we prefer dexmedetomidine as a better alternative because of its superior clinical profile. Further studies with large samples may be warranted to validate these findings.

CONCLUSION: From the present study, we conclude that dexmedetomidine prolongs the duration of sensory and motor blockade enhancing the quality of block as compared to clonidine when used as adjuvant to levobupivacaine in supraclavicular brachial plexus block for upper limb orthopaedic surgeries. Duration of analgesia was significantly prolonged with dexmedetomidine thus making it a potential adjuvant for peripheral nerve blocks.

REFERENCES:

1. Foster RH, Markham A. Levobupivacaine: a review of its pharmacology and use as a local anesthetic. *Drugs*. 2000; 59: 551–579.
2. McLeod GA, Burke D. Levobupivacaine. *Anaesthesia*. 2001; 56: 331–41.
3. Urbanek B, Duma A, Kimberger O, Huber G, Marhofer P, Zimpfer M, et al. Onset time, quality of blockade, and duration of three-in-one blocks with levobupivacaine and bupivacaine. *Anesth Analg*. 2003; 97: 888–92.
4. Eisenach JC, De Kock M, Klimscha W. Alpha (2)-adrenergic agonists for regional anesthesia. A clinical review of clonidine (1984–1995). *Anesthesiology* 1996;85:655–74
5. Murphy Damien B, Carteny Colin JL, Vincent WS. Novel analgesic adjuvants for brachial plexus block: A systemic review. *Anesth Analg*. 2000; 90: 1122–1128.
6. Raimo V, Juha M, Veijo S, Leena N, Virtanen R. Characterisation of selectivity, specificity and potency of dexmedetomidine as α_2 adrenoceptor agonist. *Eur J Pharmacol*. 1988; 150: 9–14.

ORIGINAL ARTICLE

7. Keniya VM, Ladi S, Naphade R. Dexmedetomidine attenuates sympathoadrenal response to tracheal intubation and reduces perioperative anesthetic requirement. *Indian J Anaesth.* 2011; 55: 352–357.
8. Popping DM, Elina N, Marret E, Wenk E, Tramer MR. Clonidine as an adjuvant to local anesthetic for peripheral nerve and plexus blocks: A meta-analysis of randomized trial. *Anesthesiology.* 2009; 111: 409–415.
9. Singelyn FJ, Dangoisse M, Bartholomee S, Gouverneur JM. Adding clonidine to mepivacaine prolongs the duration of anesthesia and analgesia after brachial plexus block. *Reg Anesth.* 1992; 17: 148–150.
10. Bruce BG, Green A, Blaine TA, Wesner LV. Brachial plexus blocks for upper extremity orthopaedic surgery. *J Am Acad Orthop Surg.* 2012; 20: 38–47.
11. Liisanantti O, Luukkonen J, Rosenberg PH. High-dose bupivacaine, levobupivacaine and ropivacaine in axillary brachial plexus block. *Acta Anaesthesiol Scand.* 2004; 48: 601–6.
12. Piangatelli C, De Angelis C, Pecora L, Recanatini F, Cerchiara P, Testasecca D. Levobupivacaine and ropivacaine in the infraclavicular brachial plexus block. *Minerva Anesthesiol.* 2006; 72: 217–21.
13. Obayah GM, Refaie A, Aboushanab O, Ibraheem N, Abdelazees M. Addition of dexmedetomidine to bupivacaine for greater palatine nerve block prolongs postoperative analgesia after cleft palate repair. *Eur J Anaesthesiol.* 2010; 27: 280–4.
14. Pujol E, Faulí A, Anglada MT, López A, Pons M, Fàbregas N. Ultrasound-guided single dose injection of 0.5% levobupivacaine or 0.5% ropivacaine for a popliteal fossa nerve block in unilateral hallux valgus surgery. *Rev Esp Anesthesiol Reanim.* 2010; 57: 288–92.
15. Fournier R, Faust A, Chassot O, Gamulin Z. Levobupivacaine 0.5% provides longer analgesia after sciatic nerve block using the Labat approach than the same dose of ropivacaine in foot and ankle surgery. *Anesth Analg.* 2010; 110: 1486–9.
16. Casati A, Baciarello M. Enantiomeric local anesthetics: Can ropivacaine and levobupivacaine improve our practice? *Curr Drug Ther.* 2006; 1: 85–9.
17. Guo TZ, Jiang JY, Buttermann AE, Maze M. Dexmedetomidine injection into locus coeruleus produces antinociception. *Anesthesiology.* 1996; 84: 873–881.
18. Ramio V, Juha M, Veijo S, Leena N, Virtanen R. Characterization of selectivity, specificity, and potency of medetomidine as α_2 adrenoreceptor agonist. *Eur J Pharmacol.* 1988; 150: 9–14.
19. Das, Anjan, et al. "Effect of dexmedetomidine as adjuvant in ropivacaine-induced supraclavicular brachial plexus block: A prospective, double-blinded and randomized controlled study." *Saudi journal of anaesthesia* 8. Suppl 1 (2014): S72.
20. Jones MEP, Maze M. Can we characterize the central nervous system actions of alpha-2 adrenergic agonists? *Br J Anaesth* 2001; 86(1):1-3.
21. Eisenach JC, Dekock M, Klimscha W. Alpha (2) adrenergic agonists for regional anesthesia. A clinical review of clonidine (1984-1995). *Anesthesiology* 1996; 85: 655-74.
22. Riberio RN, Naseimento JP. The use of dexmedetomidine in anesthesiology. *Rev Bras Anesthesiol* 2003; 53: 97-113.
23. Brummett CM, Padda AK, Amodeo FS, Welch KB, Lydic R. Perineural dexmedetomidine added to ropivacaine causes a dose dependent increase in the duration of thermal antinociception in sciatic nerve block in rat. *Anesthesiology.* 2009; 111: 1111–1119.

ORIGINAL ARTICLE

24. Kosugi T, Mizuta K, Fujita T, Nakashima M, Kumamoto E. High concentration of dexmedetomidine inhibits compound action potential in frog sciatic nerve without adrenoreceptor activation. *Br J Pharmacol.* 2010; 160: 1662–1676.
25. Abosedira MA. Adding clonidine or dexmedetomidine to lidocaine during Bier's block: a comparative study. *J M Sci* 2008; 8: 660–4.
26. Agarwal, Sandhya, Ritu Aggarwal, and Praveen Gupta. "Dexmedetomidine prolongs the effect of bupivacaine in supraclavicular brachial plexus block." *Journal of anaesthesiology, clinical pharmacology* 30.1 (2014): 36.
27. Swami, Sarita S., et al. "Comparison of dexmedetomidine and clonidine (α_2 agonist drugs) as an adjuvant to local anaesthesia in supraclavicular brachial plexus block: A randomised double-blind prospective study." *Indian journal of anaesthesia* 56.3 (2012): 243.
28. Biswas S, Das RK, Mukherjee G, Ghose T. Dexmedetomidine an Adjuvant to Levobupivacaine in Supraclavicular Brachial Plexus Block: A Randomized Double Blind Prospective Study. *Ethiopian Journal of Health Sciences* 2014; 24(3):203-208.
29. Memics D, Turan A, Karamanlioglu B, Pamukcu Z, Kurt I. Adding dexmedetomidine to lidocaine for intravenous regional anesthesia. *AnesthAnalg.* 2004; 98: 835–840.
30. Esmaglu A, Mizrak A, Akin A, Turk Y, Boyaci A. Addition of dexmedetomidine to lidocaine for intravenous regional anesthesia. *Eur J Anesthesiol.* 2005; 22: 447–451.
31. Erlacher W, Schuschnig C, Orlicek F, Marhofer P, Koinig H, Kapral S. The effects of clonidine on ropivacaine 0.75% in axillary perivascular brachial plexus block. *ActaAnesth Scand.* 2000; 44: 53–57.
32. Masuki S, Dinunno FA, Joyner MJ, Eisenarch JH. Selective α_2 -adrenergic properties of dexmedetomidine over clonidine in the human forearm. *J Appl Physiol* 2005; 99: 587-92.

AUTHORS:

1. Karthik G. S.
2. Sudheer R.
3. Sahajananda H.
4. S. Rangalakshmi
5. Roshan Kumar

PARTICULARS OF CONTRIBUTORS:

1. Assistant Professor, Department of Anaesthesiology, Rajarajeswari Medical College and Hospital, Bangalore.
2. Assistant Professor, Department of Anaesthesiology, Rajarajeswari Medical College and Hospital, Bangalore.
3. Professor & HOD, Department of Anaesthesiology, Rajarajeswari Medical College and Hospital, Bangalore.

FINANCIAL OR OTHER

COMPETING INTERESTS: None

4. Professor, Department of Anaesthesiology, Rajarajeswari Medical College and Hospital, Bangalore.
5. Professor, Department of Orthopaedics, Rajarajeswari Medical College and Hospital, Bangalore.

NAME ADDRESS EMAIL ID OF THE CORRESPONDING AUTHOR:

Dr. Karthik G. S,
#109-B, 6th Main, 5th Cross, 3rd Stage,
Chandrashekar Block,
BEML Layout,
Rajarajeswari Nagar, Bangalore-560098.
E-mail: drgskarthik@rediffmail.com

Date of Submission: 23/02/2015.
Date of Peer Review: 24/02/2015.
Date of Acceptance: 25/02/2015.
Date of Publishing: 03/03/2015.